

Dermatophytes in domestic animals

Francisco Javier Cabañes

Departament de Patologia i de Producció Animals, Facultat de Veterinària, Universitat Autònoma de Barcelona, Bellaterra, Barcelona, Spain

Summary

Dermatophytes are cited among the most frequent causes of dermatological problems in domestic animals. However, only a few species belonging to the genera *Microsporum* and *Trichophyton* are usually the cause of dermatophytosis in these animals. In very few cases, anthropophilic species have been mentioned as a cause of dermatophytosis in animals. However some geophilic dermatophytes are normally the cause of a relatively low number of cases of ringworm. Animals serve as reservoirs of the zoophilic dermatophytes, and their infections have considerable zoonotic importance. In this article, the occurrence and the main distinctive characteristics of the usual etiological agents of dermatophytosis, both in pets and in farm animals, are described. A simple key for the identification of these dermatophytes is included.

Key words

Dermatophytes, Dermatophytosis, Domestic animals

Dermatophytes are cited among the most frequent causes of dermatological problems in domestic animals. The superficial mycoses caused by dermatophytes are called dermatophytosis, and they are commonly referred to as ringworm or tinea. In general, dermatophytes do not invade subcutaneous or deep tissues, but pseudotumoral lesions ("mycetoma", "pseudomycetoma") affecting the subcutaneous tissues have been described in Persian cats [1,2].

Dermatophytes are classified in three genera, *Epidermophyton*, *Microsporum* and *Trichophyton*, which include about 40 accepted species. However, only a few species belonging to the genera *Microsporum* and *Trichophyton* are usually the cause of dermatophytosis in domestic animals (Table 1). They are usually divided into three ecological groups according to their main natural host or habitat: the anthropophilic (humans), the zoophilic (animals) and the geophilic (soil).

Only two species are included in the genus *Epidermophyton*. *Epidermophyton floccosum* is categorized as an anthropophilic species and only normally responsible for a small percentage of human dermatophytosis, although its occurrence in animals has been reported [3]. In very few cases, anthropophilic spe-

cies have been mentioned as a cause of dermatophytosis in animals [3]. In very special cases, anthropophilic dermatophytes, such as *T. rubrum* [4], have been isolated from the coat of healthy pets. Apparently cats, which in this case [4] were living in close contact with *T. rubrum* infected owners, were merely carriers of viable propagules of this dermatophyte.

Epidermophyton stockdaleae is categorized as a geophilic dermatophyte fungus, and so far has not been mentioned as a causal agent of dermatomycosis [5]. This species has only been isolated once before [6]. Nevertheless, most of the members of the *M. gypseum* complex, which are geophilic dermatophytes, are the cause of a relatively low number of cases of ringworm, both in humans and animals. On the other hand, some geophilic nonpathogenic dermatophytic species, such as *M. cookei*, *T. ajelloi* and *T. terrestre*, can be isolated from animal fur [7,8]. These species are included in the dermatophyte-like fungi group by some authors [9].

Animals serve as reservoirs of the zoophilic dermatophytes, and their infections have considerable zoonotic importance. Zoophilic dermatophytes such as *M. canis*, *T. mentagrophytes* var. *mentagrophytes* and *T. verrucosum* are significant causal agents of human ringworm in many areas of the world. The incidence of dermatophytosis varies according to climate and natural reservoirs. However, the pattern of the species of dermatophytes involved in dermatophytosis may be different in similar geographical conditions, both in humans and animals. It has been related, among other factors, to the decline in the incidence of animal ringworm in these areas or the degree and closeness of animal to human contact [10].

In this article, the occurrence and the main distinctive characteristics of the usual etiological agents of dermatophytosis, both in pets and in farm animals are described. A simple key for the identification of these dermatophytes is included.

Corresponding address:

Dr. Francisco Javier Cabañes
 Departament de Patologia i de Producció Animals,
 Facultat de Veterinària, Universitat Autònoma de Barcelona,
 E-08193 Bellaterra, Barcelona, Spain.
 E-mail: F.J.Cabanés@cc.uab.es

Table 1. Main etiological agents of dermatophytosis in different animal species.

Domestic animals	Dermatophytes
Cats and dogs	<i>M. canis</i> Others: <i>T. mentagrophytes</i> , <i>M. gypseum</i> , <i>M. persicolor</i>
Horses	<i>T. equinum</i> Others: <i>M. canis</i> , <i>M. equinum</i> , <i>M. gypseum</i> , <i>T. mentagrophytes</i> , <i>T. verrucosum</i>
Cattle, goats and sheep	<i>T. verrucosum</i> Others: <i>M. canis</i> , <i>M. gypseum</i> , <i>T. mentagrophytes</i> , <i>T. equinum</i>
Rabbits	<i>T. mentagrophytes</i> Other: <i>M. canis</i>
Pigs	<i>M. nanum</i> Others: <i>M. canis</i> , <i>M. gypseum</i> , <i>T. mentagrophytes</i> , <i>T. verrucosum</i>
Poultry	<i>M. gallinae</i> Other: <i>T. simii</i>

Dogs and cats

Epidemiological studies on the isolation of dermatophytes from dogs and cats with suspected lesions of dermatophytosis have been reported by different authors [11-17]. The proportion of positive samples in relation to the number of samples examined from cases of dermatophytosis varies considerably from one study to another. The relatively low prevalence of dermatophytes in dogs with suspected lesions of dermatophytosis is well documented. It ranges between 4% and 10% and few studies show higher prevalences [14,17]. With few exceptions, *M. canis* was the most common species isolated, showing a high variability in its percentages of isolation (40-90%). Other dermatophytes less commonly isolated from dogs are *T. mentagrophytes* and *M. gypseum*. These three species comprise approximately 96% of the isolated dermatophytes from dogs in the above cited epidemiological studies. *Microsporum persicolor* comprise 2% of the isolates, and the remaining 2% includes a very long list of species. In cats with suspected lesions of dermatophytosis the prevalence of dermatophytes is usually higher than in dogs, and it is usually higher than 20% [11-17]. Cats are accepted as the principal reservoir for *M. canis*. This species is the most common dermatophyte isolated from cats, with percentages of isolation higher than 90% from animals with suspected lesions of dermatophytosis. Other dermatophytes less commonly isolated from cats are *T. mentagrophytes* and *M. gypseum*. These three species comprise approximately 98% of the isolated dermatophytes from cats in the above cited epidemiological studies.

Occasionally, a variety of other dermatophytic species (e.g. *E. floccosum*, *M. cookei*, *M. fulvum*, *M. vanbreuseghemii*, *T. ajelloi*, *T. equinum*, *T. rubrum*, *T. verrucosum*, etc) have been cited as etiological agents of dermatophytosis and/or have been isolated from the fur of healthy cats and/or dogs [3,18]. However, these species are rarely isolated from these animals in the daily routine of a veterinary mycology laboratory.

Horses

Most authors [2,11,13,19] mentioned that dermatophytosis in horses is mainly produced by *T. equinum*, although other species such as *M. canis*, *M. equinum*, *M. gypseum*, *T. mentagrophytes* and *T. verrucosum* can usually be found in equine ringworm. With regard to the special characteristics of *T. equinum*, the fluffy white colony type isolates of *T. equinum* mainly from the Northern Hemisphere had nutritional requirements for nicotinic acid (*T. equinum* var. *equinum*). A dark variant of *T. equinum* var. *equinum* has recently been cited as responsible for a high percentage of ringworm in horses in the USA [2]. The usual ringworm agent affecting horses in Australia [19] lacked a complete requirement for nicotinic acid [20] (*T. equinum* var. *autotrophicum*). *Microsporum equinum* can be differentiated from *M. canis*, among other characteristics, by the smaller size of its macroconidia and its failure to perforate hair *in vitro* [21].

Cattle, goats and sheep

Trichophyton verrucosum has been cited as the major agent encountered in cases of bovine, ovine and caprine ringworm. Other species such as *M. canis*, *M. gypseum*, *T. mentagrophytes* and *T. equinum* have been isolated from some of these ruminants [10,11,13]. Many *T. verrucosum* isolates require thiamine and/or inositol [3]. However, some isolates from sheep lacked these nutritional requirements [10,17]. These ovine isolates of *T. verrucosum* have been named as *T. verrucosum* var. *autotrophicum* or '*T. ovis*' [10].

Rabbits

Trichophyton mentagrophytes is the main causal agent of ringworm in these animals [22]. However, dermatophytosis in rabbits is not exclusively caused by this species. *Microsporum canis* has been cited as an important cause of ringworm in several countries [17,23-26].

Most of the *T. mentagrophytes* complex isolates from domestic animals belong to the granular form *T. mentagrophytes* var. *mentagrophytes* [10]. They are rapidly urease positive. Major animal hosts of the other three common variants are: hedgehogs (*T. mentagrophytes* var. *erinacei*), mice (*T. mentagrophytes* var. *quinckeanum*) and humans (*T. mentagrophytes* var. *interdigitale*) [9].

Pigs

Dermatophytosis in pigs is rare and it has little effect on productivity. *Microsporum nanum* is the main cause of ringworm in these animals [3]. Other dermatophytes involved are: *M. canis*, *M. gypseum*, *T. mentagrophytes* and *T. verrucosum* [3,11,13,20,27,28].

Poultry

Dermatophytosis in poultry is also rare and it is seen in backyard flocks and those kept under poor husbandry and management conditions. *Microsporum gallinae* is the main cause of ringworm in chickens and other fowl. *Trichophyton simii* is also a cause of ringworm, mainly in India [3].

Key to the identification of the more usual dermatophytes isolated from domestic animals.

(For an overview of the species belonging to dermatophytes see the keys proposed by Rebell and Taplin [3] and Kane *et al.* [29]).

1	Macroconidia present.....	2
	Macroconidia absent	7
2	Macroconidia spindle-shaped, with rough and thick walls and frequently with a distinct beak at tip. Cells numerous (usually more than six). It perforate hair in vitro. Associated with different animal species (Figure 1)	<i>M. canis</i>
	Macroconidia small, elliptical or fusiform, similar in shape to those of <i>M. canis</i> . One to four cells (Figure 2). It does not perforate hair in vitro. Associated with horses.....	<i>M. equinum</i>
	Macroconidia thin-walled.....	3
3	Macroconidia smooth-walled.....	4
	Macroconidia rough-walled	5
4	Numerous small round microconidia in clusters, resembling unripe grapes. Macroconidia when present cigar shaped (Figure 3). Presence of coiled filaments. Urease positive. It perforate hair <i>in vitro</i>	<i>T. mentagrophytes</i>
	Microconidia narrowly pyriform, usually lateral on hyphae (Figure 4). Macroconidia rare, when present, similar to those of <i>T. mentagrophytes</i> . Urease positive. It does not perforate hair in vitro. Nicotinic acid is required by many isolates. Mainly associated with horses.....	<i>T. equinum</i>
5	Macroconidia containing more than three cells	6
	Small macroconidia egg shaped to short ellipsoidal, most containing two cells.(Figure 5) Associated with pigs.....	<i>M. nanum</i>
6	Macroconidia numerous, symmetrical, fusiform, containing up to six cells (Figure 6)	<i>M. gypseum</i>
	Macroconidia slightly echinulate or smooth, with five cells or more and frequently curved. Associated with chickens	<i>M. gallinae</i>
	Macroconidia finely echinulate (mainly at the tip) or smooth, similar to those of <i>T. mentagrophytes</i> , with predominantly six cells. Microconidia in clusters frequently on long stalks. Presence of coiled filaments.....	<i>M. persicolor</i>
7	Microconidia abundant	8
	Microconidia absent, or only a few of them are detected	9
8	Small round microconidia in clusters resembling unripe grapes (Figure 3). Presence of coiled filaments Urease positive. It perforate hair in vitro.....	<i>T. mentagrophytes</i>
	Microconidia narrowly pyriform, usually lateral on hyphae (Figure 4). Urease positive. It does not perforate hair in vitro. Nicotinic acid is required by many isolates. Mainly associated with horses	<i>T. equinum</i>
9	Long chains of densely compacted chlamydospores present (Figure 7) Many isolates require thiamine and/or inositol. Mainly associated with cattle	<i>T. verrucosum</i>

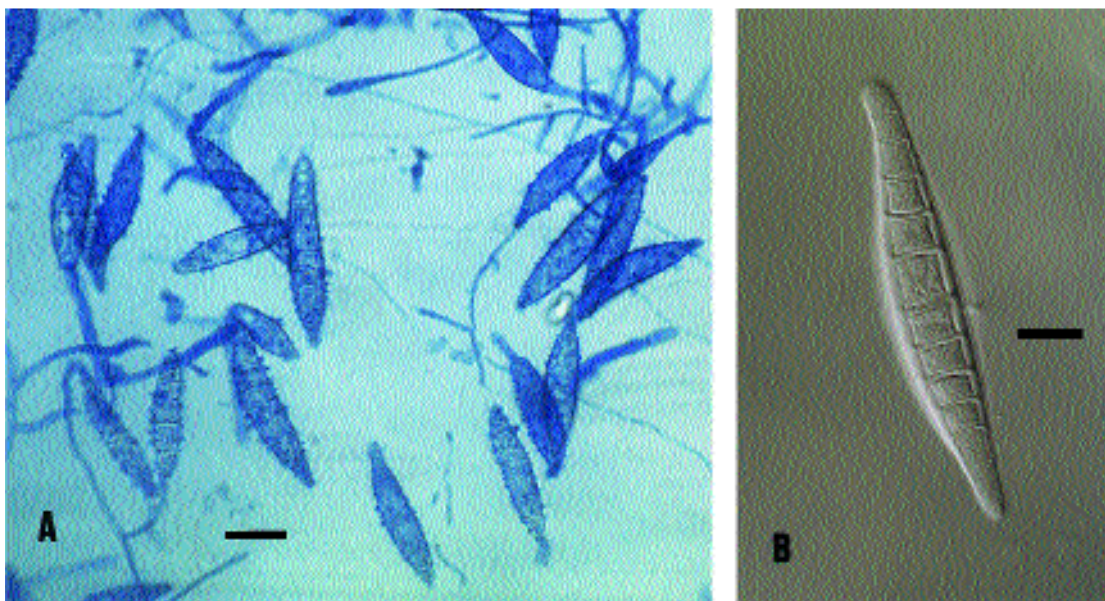


Figure 1. Macroconidia of *M. canis*. A. Bar = 20 µm. B. Bar = 10 µm.

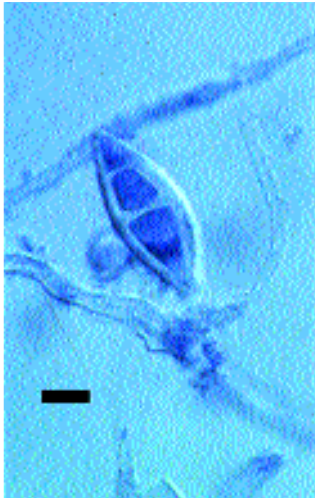


Figure 2. Macroconidium of *M. equinum*. Bar = 5 μ m.

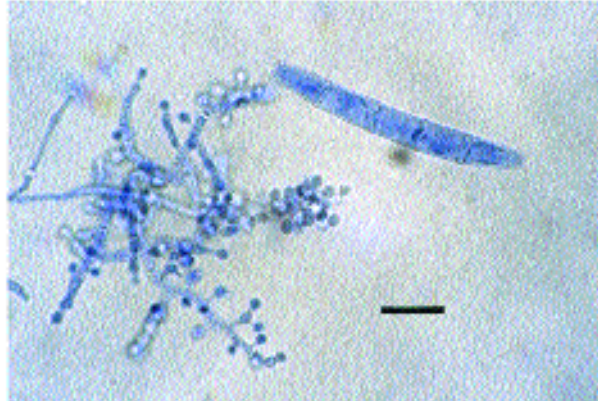


Figure 3. Macroconidium and microconidia of *T. mentagrophytes*. Bar = 10 μ m.

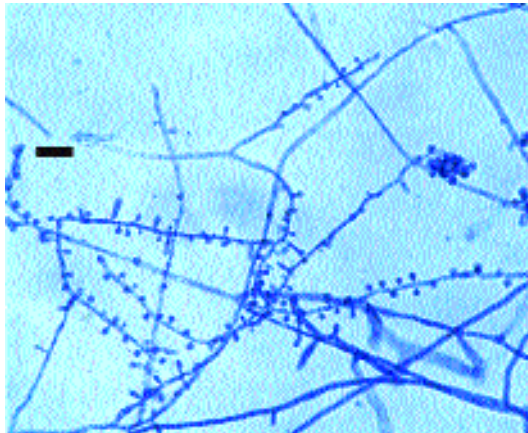


Figure 4. Microconidia of *T. equinum*. Bar = 10 μ m.

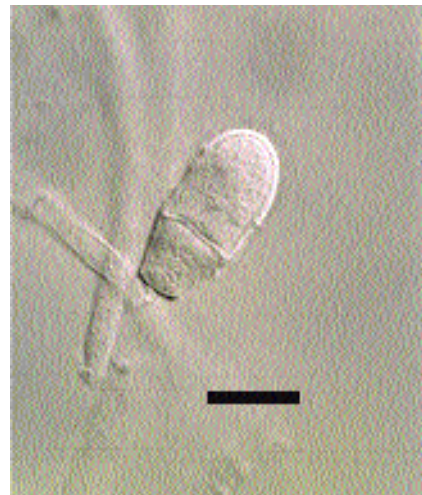

Figure 5. Macroconidium of *M. nanum*. Bar = 10 μ m.

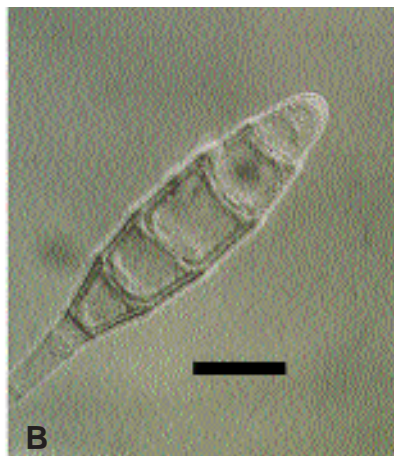
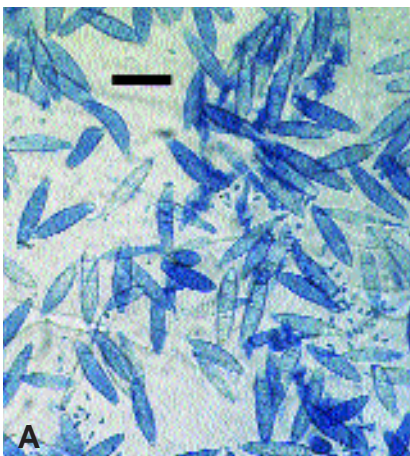


Figure 6. *Microsporum gypseum*. A. Macroconidia and microconidia. Bar = 30 μ m. B. Macroconidium. Bar = 10 μ m.

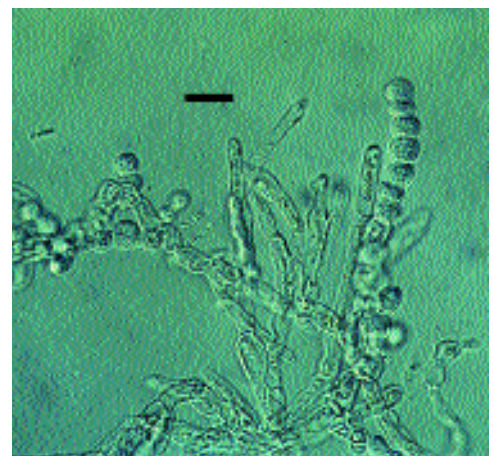


Figure 7. Chlamydospores and hyphal swellings of *T. verrucosum*. Bar = 10 μ m.

References

1. Medleau L, Rakich PM. *Microsporium canis* pseudomycetomas in a cat. *J Am Anim Hosp Assoc* 1994; 30: 573-576.
2. Richard JL, Debey MC, Chermette R, Pier AC, Hasegawa A, Lund A, Bratberg AM, Padhye AA, Connole MD. Advances in veterinary mycology. *J Med Vet Mycol* 1994; 32 (Suppl 1): 169-187.
3. Rebell G, Taplin D. Dermatophytes, their recognition and identification. Coral Gables, University of Miami Press, 1979.
4. Moriello KA, Deboer DJ. Fungal flora of the coat of pet cats. *Am J Vet Res* 1991; 52: 602-606.
5. Cabañes FJ, Abarca ML, Bragulat MR, Calvo MA. Experimental dermatophytoses produced by *E. floccosum* in guinea pigs. *Mycopathologia* 1987; 98: 45-47.
6. Prochacki H, Engelhardt-Zasada C. *Epidermophyton stockdaleae* sp. nov. *Mycopath Mycol Appl* 1974; 54: 341-345.
7. Cabañes FJ, Abarca ML, Bragulat MR, Castellá G. Seasonal study of the fungal biota of the fur of dogs. *Mycopathologia* 1996; 133: 1-7.
8. Simpanya MF, Baxter M. Isolation of fungi from the pelage of cats and dogs using hairbrush technique. *Mycopathologia* 1996; 134: 129-133.
9. Kwon-Chung KJ, Bennett JE. *Medical mycology*, Philadelphia, Lea and Febiger, 1992.
10. Pier AC, Smith JMB, Alexiou H, Ellis DH, Lund A, Pritchard RC. Animal ringworm-its aetiology, public health significance and control. *J Med Vet Mycol* 1994; 32 (Suppl 1): 133-150.
11. Pepin GA, Austwick PKC. II.- Skin disease, mycological origin. *Vet Rec* 1968; 82: 208-214.
12. Aho R. Studies on fungal flora in hair from domestic and laboratory animals suspected of dermatophytosis. I. Dermatophytes. *Acta Path Microb Scand Sect B* 1980; 88: 79-83.
13. Stenwig H. Isolation of dermatophytes from domestic animals in Norway. *Nord Vet Med* 1985; 37: 161-169.
14. Faggi E, Saponetto N, Sagone M. Dermatophytes isolés des carnivores domestiques a Florence (Italie): enquête épidémiologique. *Bull Soc Fr Mycol Med* 1987; 16: 297-301.
15. Lewis DT, Foil CS, Hosgood G. Epidemiology and clinical features of dermatophytosis in dogs and cats at Louisiana State University: 1981-1990. *Vet Dermatol* 1991; 2: 53-58.
16. Sparkes AH, Gruffydd-Jones TJ, Shaw SE, Wright AI, Stokes CR. Epidemiological and diagnostic features of canine and feline dermatophytosis in the United Kingdom from 1956 to 1991. *Vet Rec* 1993; 133: 57-61.
17. Cabañes FJ, Abarca ML, Bragulat MR. Dermatophytes isolated from domestic animals in Barcelona, Spain. *Mycopathologia* 1997; 137: 107-113.
18. Solans C. Etiología de las dermatofitosis caninas: revisión. *Rev Iber Micol* 1988; 5: 41-48.
19. Connole MD. Review of animal mycoses in Australia. *Mycopathologia* 1990; 111: 133-164.
20. Smith JMB, Jolly RD, Georg LK, Connole MD. *Trichophyton equinum* var. *autotrophicum*; its characteristics and geographical distribution. *Sabouraudia* 1968; 6: 296-304.
21. Padhye AA, Weitzman I, Ajello L. Mating behaviour of *Microsporium equinum* with *Nannizzia otae*. *Mycopathologia* 1979; 69: 87-90.
22. Hagen KW, Gorham JR. Dermatomycoses in fur animals: chinchilla, ferret, mink and rabbit. *Vet Med Small Anim Clin* 1972; 67: 43-48.
23. Cutsem J van, Gerven F van, Geerts H, Rochette F. Treatment with enilconazole spray of dermatophytosis in rabbit farms. *Mykosen* 1985; 28: 400-407.
24. González JF, Solans C, Latre MV. *Microsporium canis* productor de dermatofitosis en conejos. *Rev Iber Micol* 1988; 5: 84-89.
25. Zaror L, Casas S. *Microsporium canis* en conejos Angora sanos (Valdivia-Chile). *J Vet Med B* 1988; 35: 204-206.
26. Torres JM, Dronda MA, Rosell J, Madrenys N. Incidence of dermatophytoses in rabbit farms in Catalonia, Spain, and its repercussion on human health. *Eur J Epidemiol* 1992; 8: 326-329.
27. González JF, Latre MV, Solans C, Verde MT. Dermatophytosis of pigs by *Trichophyton mentagrophytes*. *Mycopathologia* 1988; 101: 161-164.
28. González JF, Bárcena MC, Gómez F, Amigot JA. An outbreak of dermatophytosis in pigs caused by *Microsporium canis*. *Mycopathologia* 1995; 129: 79-80.
29. Kane J, Summerbell R, Sigler L, Kraiden S, Land G. *Laboratory handbook of dermatophytes: a clinical guide and laboratory handbook of dermatophytes and other filamentous fungi from skin, hair, and nails*. Belmont, Star Publishing Company, 1997.

This chapter is dedicated to G. Rebell and D. Taplin and their manual: "Dermatophytes, their recognition and identification", not only for inspiring me to write this chapter but for helping me to identify dermatophytes and teach this topic for many years.